

Hydradermabrasion: an innovative modality for nonablative facial rejuvenation

Bruce M Freedman, MD, FACS

Plastic Surgery Associates of Northern Virginia, McLean, VA

Summary

Background Hydradermabrasion is a relatively new procedure that combines crystal-free microdermabrasion with the pneumatic application of an antioxidant-based serum.

Objective This study aims to validate the safety and efficacy of hydradermabrasion for nonablative facial rejuvenation and to determine whether antioxidant levels could be increased in the skin with this technique.

Methods Twenty female volunteers, aged 34–56 years, were randomized into two groups. Group A underwent a series of six facial hydradermabrasion treatments using a polyphenolic antioxidant serum spaced 7–10 days apart. In Group B, the same polyphenolic antioxidant serum was applied manually to the skin for a total of six treatments at 7- to 10-day intervals. Digital photographs, skin biopsies, and skin polyphenolic antioxidant levels were obtained prior to and after the treatment regimen. Patient surveys were taken following the study.

Results In Group A, treated skin demonstrated increased epidermal thickness, papillary dermal thickness, and polyphenolic antioxidant levels ($P < 0.01$). There was replacement of elastotic dermal tissue, collagen hyalinization, and increased fibroblast density. Fine lines, pore size, and hyperpigmentation were decreased following treatment. There were no reported complications. In Group B, there was no change in skin structure, antioxidant levels, or clinical skin attributes.

Conclusion Hydradermabrasion effectively improved skin quality both clinically and histologically. There were no changes to suggest that pneumatic serum application adversely affected dermal components. After hydradermabrasion, skin polyphenolic antioxidant levels were increased. In contrast, the intermittent manual application of the polyphenolic antioxidant serum without the microdermabrasion element did not result in detectable skin changes.

Keywords: facial rejuvenation, hydradermabrasion, topical antioxidants

Introduction

Over the past decade, microdermabrasion has been accepted as a safe, reliable method for nonablative facial rejuvenation.^{1–3} The clinical and histological changes

associated with crystal-based microdermabrasion have been reported. These have included reduction in fine lines and hyperpigmentation, decreased pore size, and improved skin texture. Likewise, thickening and reorganization of the papillary dermal matrix has been demonstrated.^{4,5}

In an effort to augment the changes observed following microdermabrasion, clinicians began using other modalities, such as intense pulsed light and topical chemical solutions concomitantly with microdermabrasion. Responses such

Correspondence: Bruce M Freedman, MD, 8180 Greensboro Drive #1015, McLean, VA 22102. E-mail: bfreedman58@aol.com

Accepted for publication May 18, 2008

as more vigorous epidermal peeling and greater reduction in dyschromia were qualitatively and anecdotally reported with the combinations. In addition, technical modifications were made to simplify yet enhance clinical outcomes. Crystal-free microdermabrasion was developed to eliminate the need for costly, cumbersome crystals and to reduce the potential for eye injury.^{6,7} The most recent refinement has been the introduction of pneumatically applied topical serums to more efficiently deliver various chemical compounds to the skin.

Hydradermabrasion, the term coined to describe the procedure that combines crystal-free microdermabrasion using an abrading tip with the pneumatic application of an antioxidant-rich serum, represents another step in the evolution of microdermabrasion technology. Recently, there has been substantial interest in the effects of antioxidants on skin health. It has been theorized that antioxidants protect skin from ultraviolet radiation damage, reverse photodamage, and improve collagen synthesis.^{8–10} However, the majority of basic science research in this area to date has been *in vitro* or in animal models, while clinical research has mostly been limited to observational data.^{11–13}

This study was designed to identify the histological and clinical changes observed following hydradermabrasion and to determine whether skin antioxidant levels could be increased *in vivo* when an antioxidant serum was used.

Materials and methods

Patients

Twenty female volunteers, aged 34–56 years with Fitzpatrick skin types I–IV, were randomly assigned into two groups. They consented to participate in a study to evaluate the effects of hydradermabrasion. The study conformed to the guidelines of the 1975 Declaration of Helsinki. Each patient was healthy and advised not to use concomitant skin therapy, such as tretinoin or glycolic acid 6 weeks before or during the study period. Digital photographs were taken, and 2-mm full-thickness skin biopsy specimens were obtained from the left preauricular area. Skin polyphenolic antioxidant levels were obtained from the left cheek using a non-invasive optical device: the Biophotonic Scanner (Pharmanex, Provo, UT). This technology employed laser energy at 473 nm and 10 mW power to stimulate molecules containing carbon–carbon double bonds, generating an optical fingerprint that was captured by a highly sensitive detector. The data were then processed and calculated using Raman scattering spectroscopic analysis that has been validated in humans *in vivo*.¹⁴ A linear relationship

has been established between antioxidant concentration and Raman intensity, indicating that absolute Raman intensity counts are a biomarker for skin antioxidant levels. In order to validate the technique for this study, baseline values were obtained from the subjects' ventral forearm skin. A polyphenolic-based serum (AntiOx™ 6, Edge Systems Corporation, Signal Hill, CA) containing polyphenolic flavonoids and polyphenolic diterpenes (e.g., epigallocatechin, ursolic acid) was manually applied to the forearm skin and allowed to dry. Raman spectroscopic analysis was repeated. Postserum application values increased significantly from $16\,000 \pm 4\,000$ to $35\,000 \pm 6\,000$ ($P < 0.01$). These polyphenolic compounds were most likely the biomarkers responsible for the increase. This is due to the fact that these polyphenolic compounds and the carotenoids, which were the biomarkers used by Hata *et al.*, have a comparable spectral Raman peak at $1\,520\text{ cm}^{-1}$.^{15,16}

In Group A ($n = 10$), a series of hydradermabrasion treatments was performed. A single operator using a crystal-free microdermabrasion device (HydraFacial™ Tower System, Edge Systems Corporation) treated all participants. Each treatment protocol consisted of facial skin cleansing followed by two passes over the face with the abrading spiral tip handpiece of the crystal-free microdermabrasion unit set at 180 mmHg. Then the polyphenolic-based antioxidant serum was pneumatically applied to the face at 20 mmHg. The average treatment lasted approximately 20 min and was repeated at 7- to 10-day intervals for a total of six treatments. In Group B ($n = 10$), the polyphenolic-based antioxidant serum was manually applied to the face and allowed to dry. This treatment was performed at 7- to 10-day intervals for a total of six treatments.

Two weeks following the sixth treatment, digital photographs, skin biopsies, and skin polyphenolic antioxidant levels were repeated in both groups. Patient evaluations were obtained to identify clinical skin changes following facial hydradermabrasion. Using a scale of 1–4 (1 = no improvement, 4 = significant improvement), patients were asked to assess changes in the following skin attributes: pore size, fine lines, hyperpigmentation, texture, hydration, and tightness.

Each skin biopsy was fixed in a 10% buffered formaldehyde solution, embedded in paraffin, and cut in 4- μm sections. Sections were stained with standard hematoxylin and eosin for light microscopy. The slides were reviewed in a blinded fashion, to evaluate epidermal and papillary dermal thickness as well as cellular and extracellular elements. An Olympus microscope was used and precision measurements were performed using a calibrated micrometer at $\times 40$ magnification. Fibroblast density in the papillary

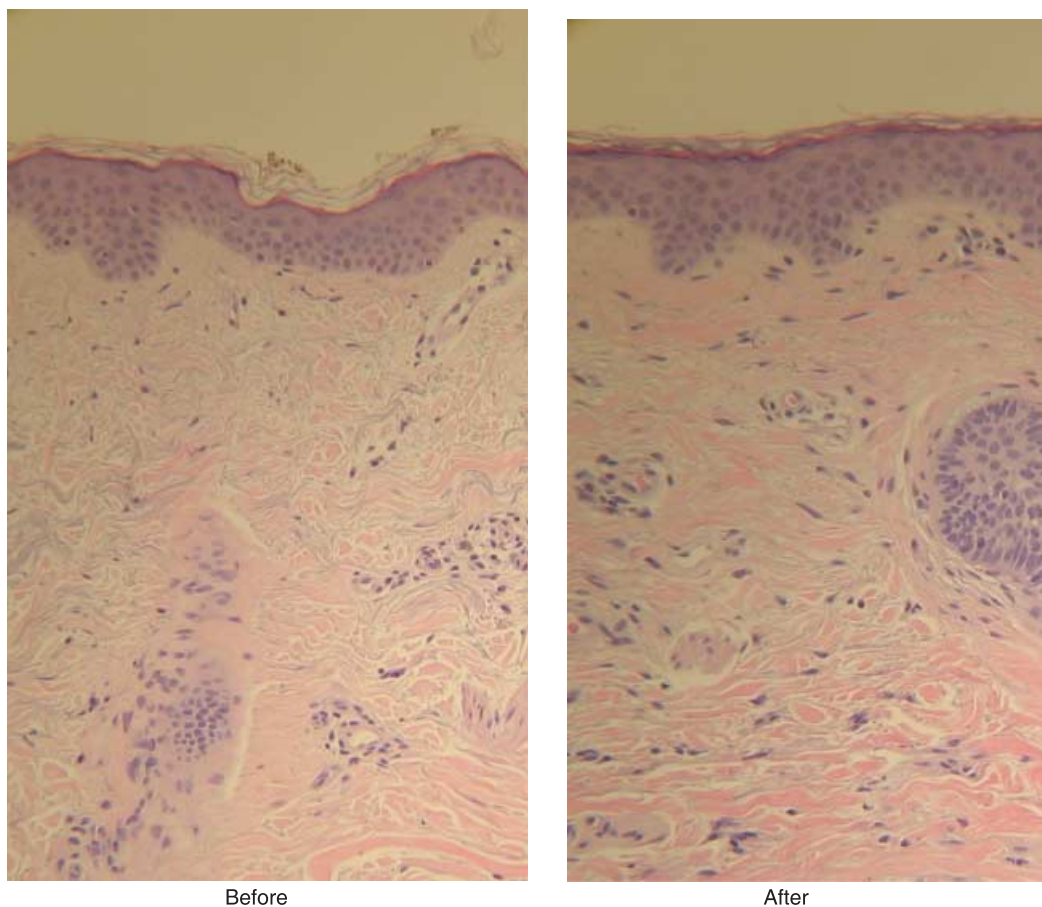


Figure 1 Histological features observed prior to and following a series of hydradermabrasion with an antioxidant serum (hematoxylin and eosin; original magnification $\times 20$).

dermis was determined by randomly viewing five fields under $\times 100$ magnification with oil immersion and averaging the number of fibroblasts per high-powered field.

Statistical analysis

The Pearson's χ^2 test was used to compare treatment Groups A and B with respect to age, gender, and skin types. These parameters were found to be similar indicating that the patients had been effectively randomized such that the subject variables did not influence outcome variables. Therefore, a two-sided paired *t*-test was justified to identify statistical differences in epidermal and papillary dermal thickness fibroblast density and skin polyphenolic antioxidant levels within each group and between groups. A *P*-value of less than or equal to 0.01 was used to declare statistical significance.

Results

In Group A, the epidermal thickness increased from $50 \pm 7 \mu\text{m}$ to $79 \pm 10 \mu\text{m}$ ($P < 0.01$) following a series of six hydradermabrasion treatments. Papillary dermal thickness also increased from $290 \pm 16 \mu\text{m}$ to $410 \pm 25 \mu\text{m}$ ($P < 0.01$). When compared to pretreatment tissue, treated tissue contained noticeable replacement of elastotic extracellular matrix with thicker, horizontally oriented collagen fibers. This hyalinization was associated with greater fibroblast density (Fig. 1). Raman intensity units used as a biomarker for skin polyphenolic antioxidant levels increased in all study participants. The pretreatment value obtained in the study group was $14\,700 \pm 3000$; this increased to $22\,300 \pm 5000$ after treatment. Using the patients as their own controls, this represented a 32% increase ($P < 0.01$) following hydradermabrasion treatment (Table 1). A majority of patients reported significant or noticeable improvements

Table 1 Results from Group A denoting changes following hydradermabrasion with a polyphenolic antioxidant serum.

N = 10	Before treatment	After treatment	
Epidermal thickness (µm)	50 ± 7	79 ± 10	<i>P</i> < 0.01
Papillary dermal thickness (µm)	290 ± 16	410 ± 25	<i>P</i> < 0.01
Fibroblast density (per high-powered field)	3.9 ± 0.3	7.9 ± 0.4	<i>P</i> < 0.01
Skin polyphenolic antioxidant level (Raman intensity units)	14 700 ± 3000	22 300 ± 5000	<i>P</i> < 0.01

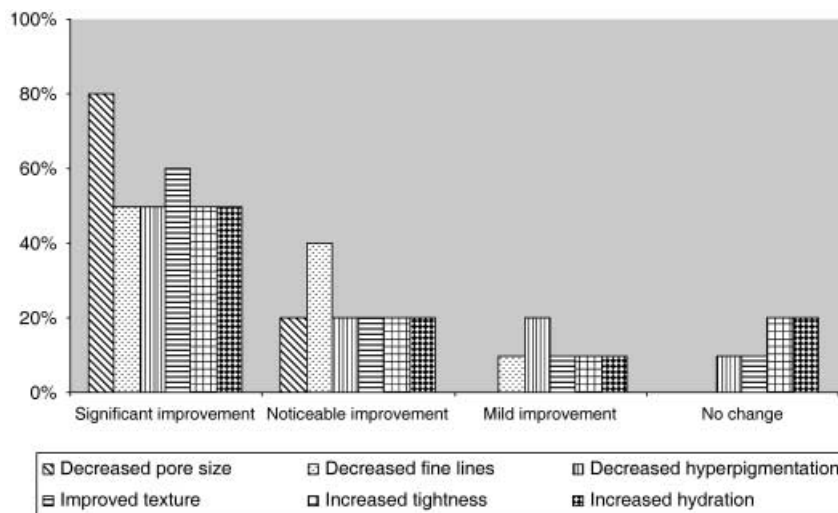


Figure 2 Patient self-assessment illustrating changes in skin attributes following hydradermabrasion with an antioxidant serum.

Table 2 Results from Group B denoting changes following manual application with a polyphenolic antioxidant serum.

N = 10	Before treatment	After treatment	
Epidermal thickness (µm)	51 ± 8	48 ± 6	NS
Papillary dermal thickness (µm)	280 ± 25	290 ± 28	NS
Fibroblast density (per high-powered field)	3.8 ± 0.4	3.8 ± 0.5	NS
Skin polyphenolic antioxidant level (Raman intensity units)	15 500 ± 4000	16 000 ± 4500	NS

in all of the surveyed skin conditions. Qualitatively, decreased pore size, decreased fine lines, and decreased hyperpigmentation were most commonly observed (Fig. 2). No complications were reported by or noted in any of the patients. Figure 3 illustrates the clinical improvement following a series of hydradermabrasion treatments.

In Group B, there was no statistical increase in epidermal or papillary dermal thickness. There was no observable change in the dermal structure or in fibroblast density. Likewise, the calculated Raman intensity counts prior to (15 500 ± 4000) and following (16 000 ± 4500) the manual application of the polyphenolic-based antioxidant serum were statistically unchanged (Table 2). Group B

patients reported no change in any of the surveyed skin conditions following manual application of the serum.

Furthermore, comparisons between Group A posttreatment parameters and Group B posttreatment parameters (Tables 1 and 2) demonstrated statistically significant increases in epidermal and papillary dermal thickness, fibroblast density, and Raman intensity counts in Group A (*P* < 0.01).

Discussion

The public's interest in and desire for healthier and more youthful skin has stimulated the development of more

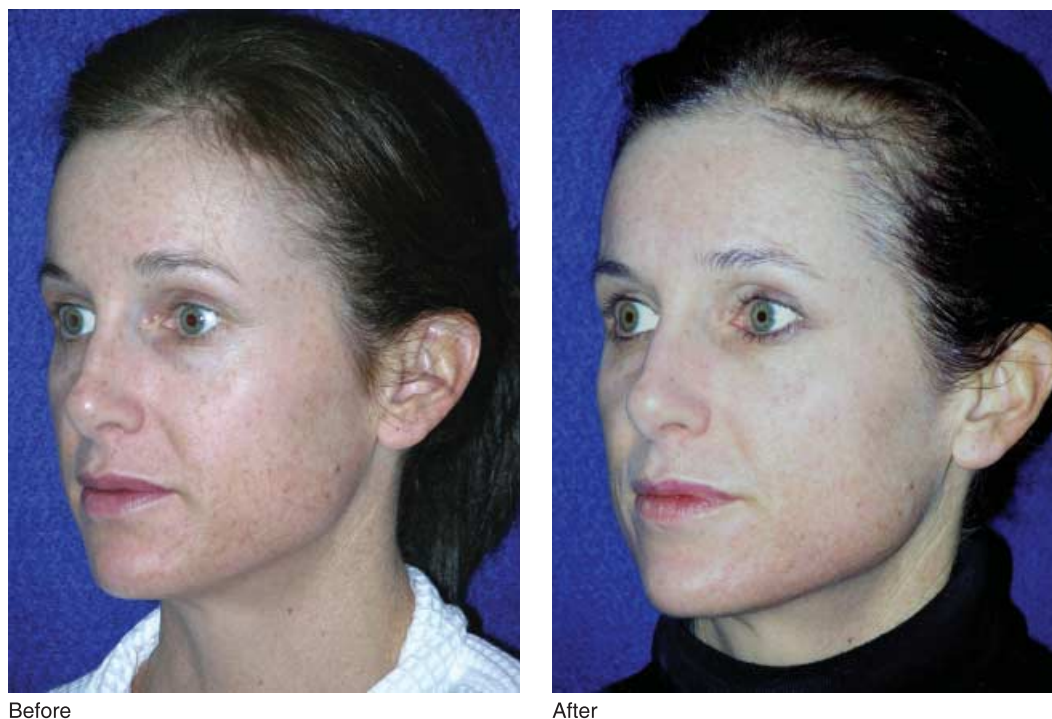

Figure 3 A 42-year-old woman shown before and after a series of hydradermabrasion treatments with an antioxidant serum.

sophisticated methods for skin rejuvenation. For example, microdermabrasion, a popular nonablative technique, has undergone several modifications and has even been combined with other modalities. This study was designed to evaluate some of the changes in microdermabrasion delivery and to determine their safety and efficacy.

Hydradermabrasion has been recently introduced as a crystal-free, vacuum-assisted microdermabrasion procedure with the pneumatic application of an antioxidant-rich serum. This study demonstrated that a series of six hydradermabrasion treatments resulted in epidermal and papillary dermal thickening with replacement of elastotic tissue and deposition of new collagen fibers. The increase in fibroblast density further confirmed the activation of a reparative process. Clinical improvement was documented photographically, and patients noted qualitative improvement in several skin attributes. These findings highlight the benefits and efficacy of the hydradermabrasion process.

The study results are also notable for the following. First, the data dispel the concept that salt crystals are necessary to produce change. Karimipour *et al.* reported that aluminum oxide crystal abrasion was necessary for initiation of the dermal remodeling cascade.¹⁷ Our findings conclude that salt crystals are not required in the

microdermabrasion process as long as another abrading component is present. In hydradermabrasion, that component is the abrading spiral tip handpiece. Second, this study demonstrates that there were no deleterious effects following the pneumatic application of an antioxidant serum to the skin. There were no histological signs of microgranulomas or focal dermal separation. Clinically, there were no reports of focal scarring, pigment problems, or texture abnormalities following treatment. These data support the safety of the hydradermabrasion process.

This study also demonstrated that polyphenolic compounds in an antioxidant-rich mixture are detectable in the skin following topical application. These polyphenols have been associated with skin photoprotection and antiaging properties.¹⁸ However, in order to be detected, these compounds had to be applied immediately following a microdermabrasion procedure; the manual application of the serum alone did not result in increased levels of polyphenolic antioxidants. The hydradermabrasion process (the combination of microdermabrasion and the pneumatic application of the antioxidant serum) also resulted in changes in skin architecture; this was not seen with the manual application of the polyphenolic antioxidant serum. It has been shown that the flux and skin deposition of vitamin C across microdermabrasion-treated

skin was approximately 20-fold higher than that across intact skin.¹⁹ The changes in skin permeability immediately following microdermabrasion are most likely responsible for the increased uptake of the antioxidants into the skin. It has been estimated that the back-scattered Raman light originates from a maximum sampling depth of 250 μm .¹⁵ This would place the polyphenolic antioxidants applied in this study within the papillary dermis. It has been postulated that increased resident levels of polyphenolic antioxidants in the skin can reduce photodamage and improve skin quality.²⁰ It appears that hydradermabrasion creates this scenario and may enhance the beneficial skin effects of antioxidants.

Hydradermabrasion may represent an excellent model with which to investigate the effects of pneumatically applied compounds, such as antioxidants, in the dermal remodeling process. Further research in this area may shed light on skin rejuvenation at a molecular level.

Acknowledgments

The author would like to acknowledge Dr. James Henry, Department of Pathology, Reston Hospital Center, for his assistance with the histological analysis, and Dr. Ian H. Dinwoodie, Department of Mathematics, Duke University, for his guidance and statistical analysis of the data.

References

- Freedman BM, Rueda-Pedraza E, Earley RV. Clinical and histologic changes determine optimal treatment regimens for microdermabrasion. *J Dermatolog Treat* 2002; **13**: 1–8.
- Spencer JM, Kurtz ES. Approaches to document the efficacy and safety of microdermabrasion procedure. *Dermatol Surg* 2006; **32**: 1553–7.
- Balla M, Thami GP. Microdermabrasion: reappraisal and brief review of literature. *Dermatol Surg* 2006; **32**: 809–14.
- Freedman BM, Rueda-Pedraza E, Waddell SP. The epidermal and dermal changes associated with microdermabrasion. *Dermatol Surg* 2001; **27**: 1031–3.
- Coimbra MD, Rohrich MD, Chao J, Brown SA. A prospective controlled assessment of microdermabrasion for damaged skin and fine rhytides. *Plast Reconstr Surg* 2004; **113**: 1438–43.
- Hexsel D, Maszzuco R, Dal'Forno T, Zechmeister D. Microdermabrasion followed by a 5% retinoid acid chemical peel vs. a 5% retinoid acid chemical peel for the treatment of photoaging – a pilot study. *J Cosmet Dermatol* 2005; **4**: 111–6.
- Katz BE, Truong S, Maiwald DC, Frew KE, George D. Efficacy of microdermabrasion preceding ALA application in reducing the incubation time of ALA in laser PDT. *J Drugs Dermatol* 2007; **6**: 140–2.
- Vayail PK, Elmets CA, Katyar SK. Treatment of green tea polyphenols in hydrophilic cream prevents UVB-induced oxidation of lipids and proteins, depletion of antioxidant enzymes and phosphorylation of MAPK proteins in SKH-1 hairless mouse skin. *Carcinogenesis* 2003; **24**: 927–36.
- Fujimura T, Tsukahara K, Moriwaki S, Hotta M, Kitahara T, Takema Y. A horse chestnut extract, which induces contraction forces in fibroblasts, is a potent anti-aging ingredient. *J Cosmet Sci* 2006; **57**: 369–76.
- Burke KE. Photodamage of the skin: protection and reversal with topical antioxidants. *J Cosmet Dermatol* 2004; **3**: 149–55.
- Anstey AV. Systemic photoprotection with α -tocopherol (vitamin E) and β -carotene. *Clin Exp Dermatol* 2002; **27**: 170–6.
- Lin JY, Selim MA, Shea CR *et al*. UV photoprotection by combination topical antioxidants vitamin C and vitamin E. *J Am Acad Dermatol* 2003; **48**: 866–74.
- Dreher F, Maibach H. Protective effects of topical antioxidants in humans. *Curr Probl Dermatol* 2001; **29**: 157–64.
- Zidichovski JA, Poole SJ, Gellerman W *et al*. Clinical validation of a novel Raman spectroscopic technology to non-invasively assess carotenoid status in humans. *J Am Coll Nutr* 2004; **25**: 468–70.
- Hata TR, Scholtz TA, Ermakov IV *et al*. Non-invasive Raman spectroscopic detection of carotenoids in human skin. *J Invest Dermatol* 2000; **115**: 44–8.
- de Jong JJ, Browne WR, Walko M *et al*. Raman scattering and FT-IR spectroscopic studies on dithienylethene switches – towards non-destructive optical readout. *Org Biomol Chem* 2006; **4**: 2387–92.
- Karimipour DJ, Kang S, Johnson TM *et al*. Microdermabrasion with and without aluminum oxide crystal abrasion: a comparative molecular analysis of dermal remodeling. *J Am Acad Dermatol* 2006; **54**: 405–10.
- Katiyar SK, Elmets CA. Green tea polyphenolic antioxidants and skin photoprotection. *Int J Oncol* 2001; **18**: 1307–13.
- Lee WR, Shen SC, Kuo-Hsien W, Hu CH, Fang JY. Lasers and microdermabrasion enhance and control topical delivery of vitamin C. *J Invest Dermatol* 2003; **121**: 1118–25.
- Chiu A, Kimball AB. Topical vitamins, minerals and botanical ingredients as modulators of environmental and chronological skin damage. *J Br Dermatol* 2003; **149**: 681–91.